

ستون مهره

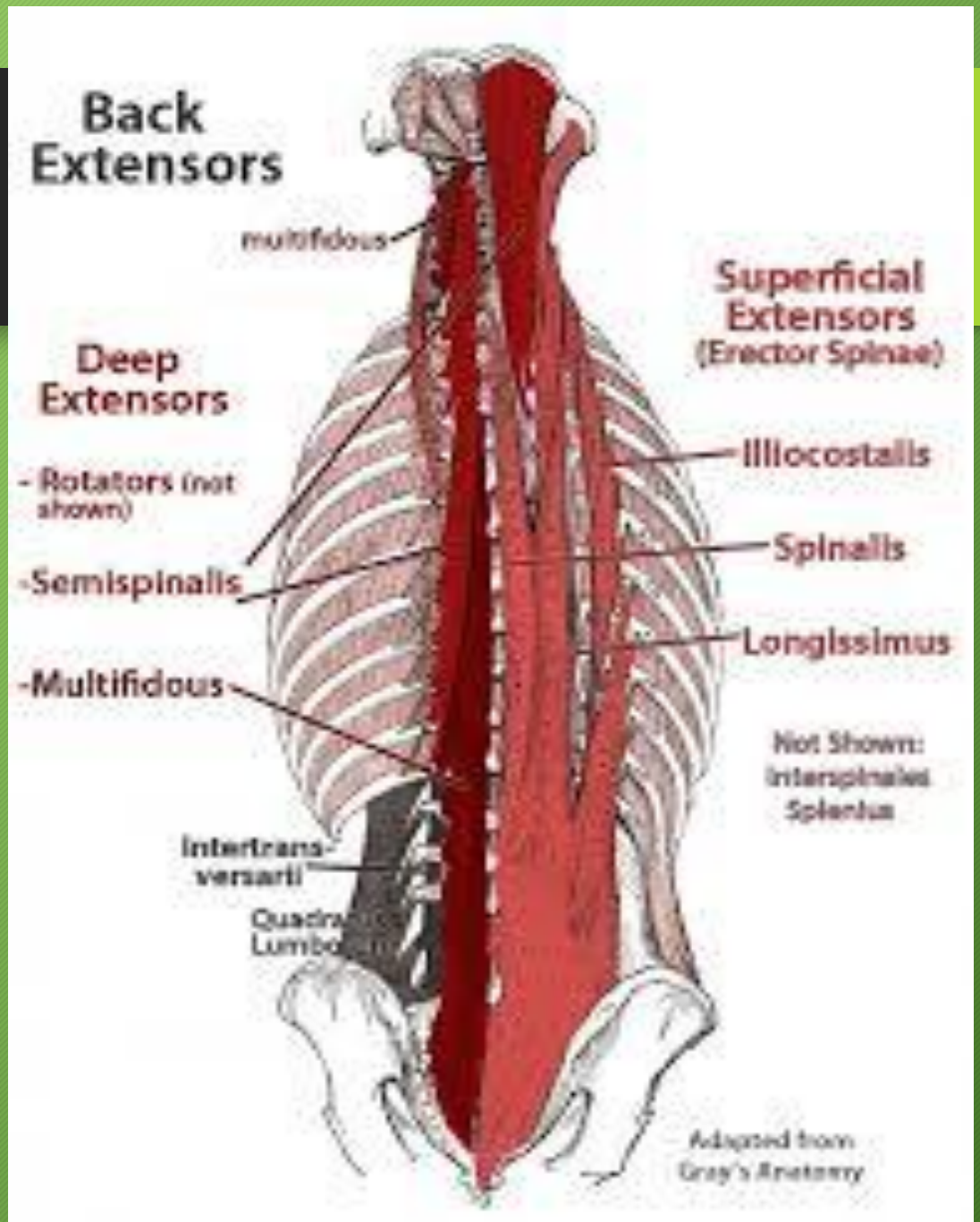


شهناز زمانی

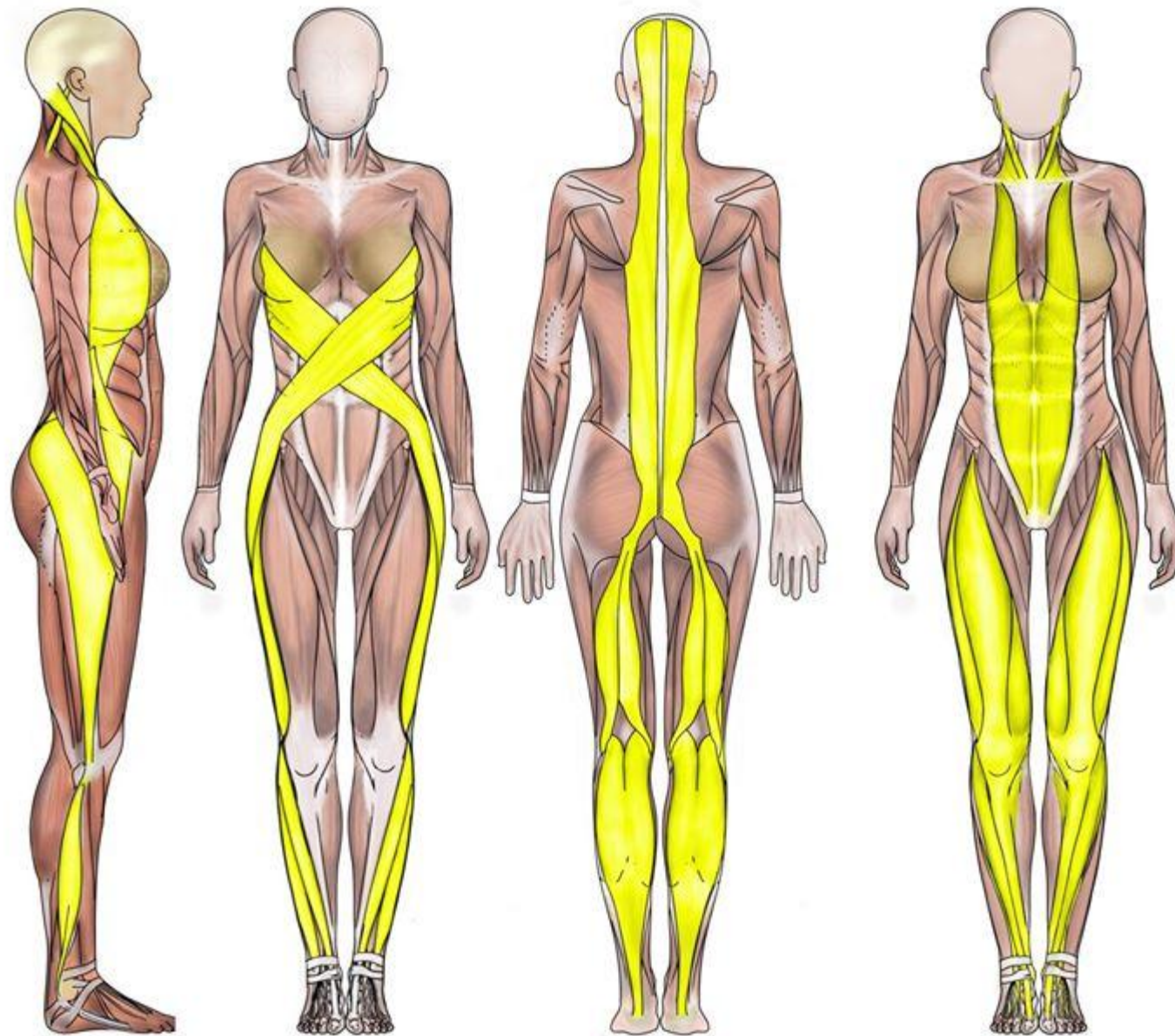
کارشناس ارشد حرکات اصلاحی

۰۹۱۴۰۰۳۸۹۸۷

PARAVERTEBRAL MUSCLE



POSTURAL MUSCLE

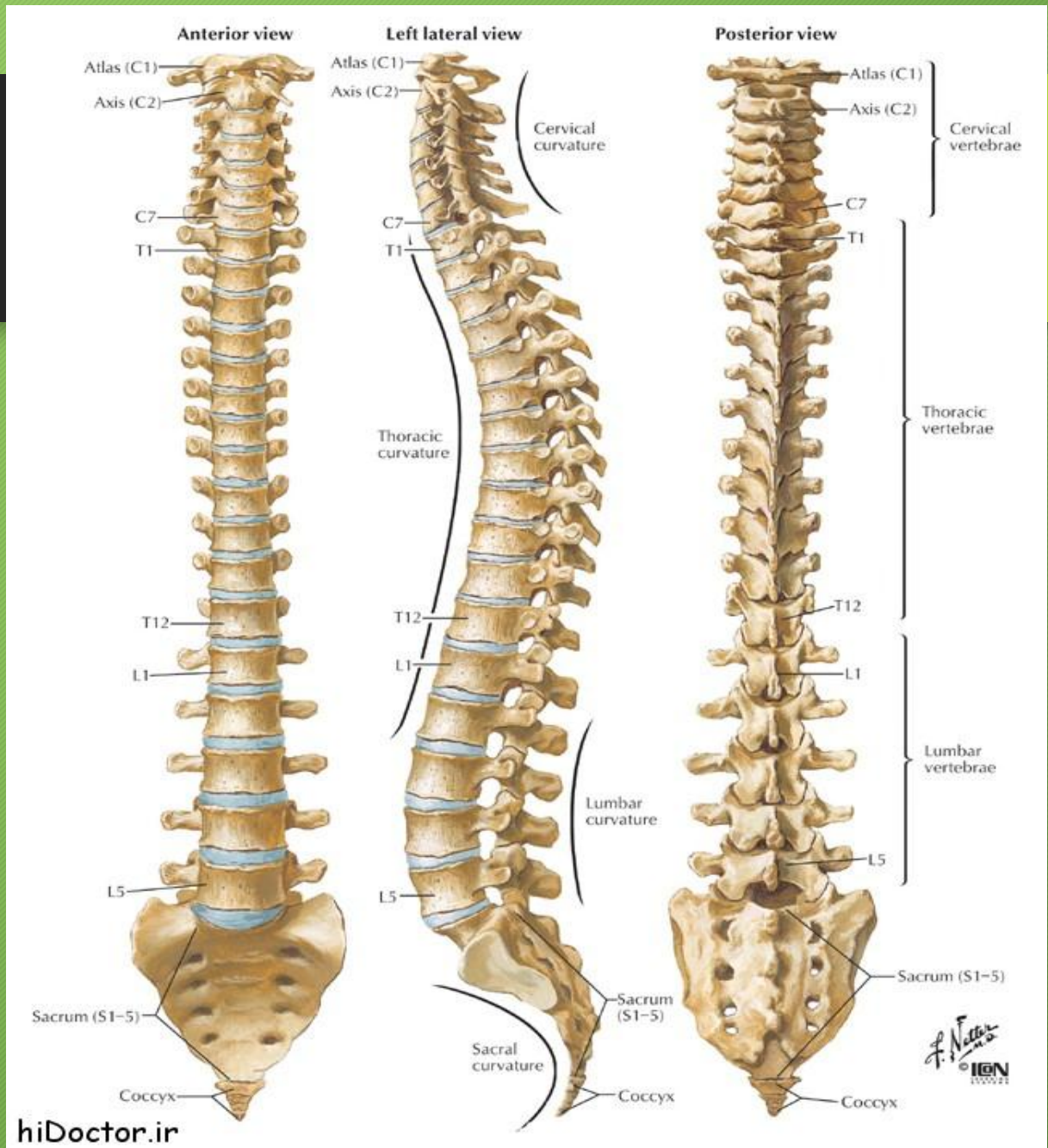


Lateral Line

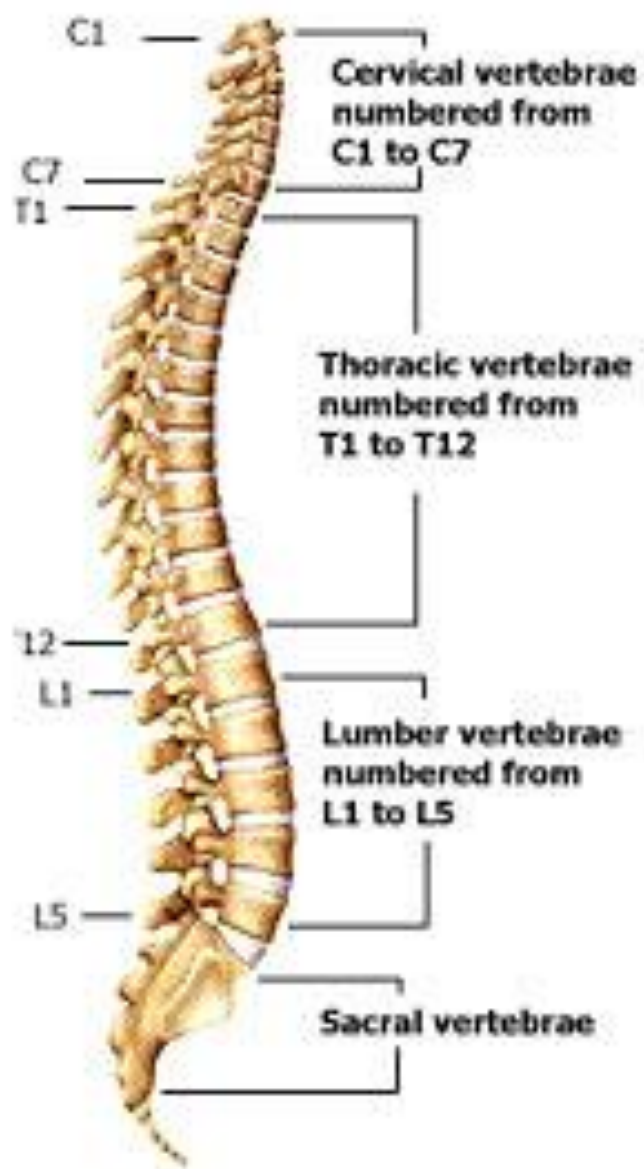
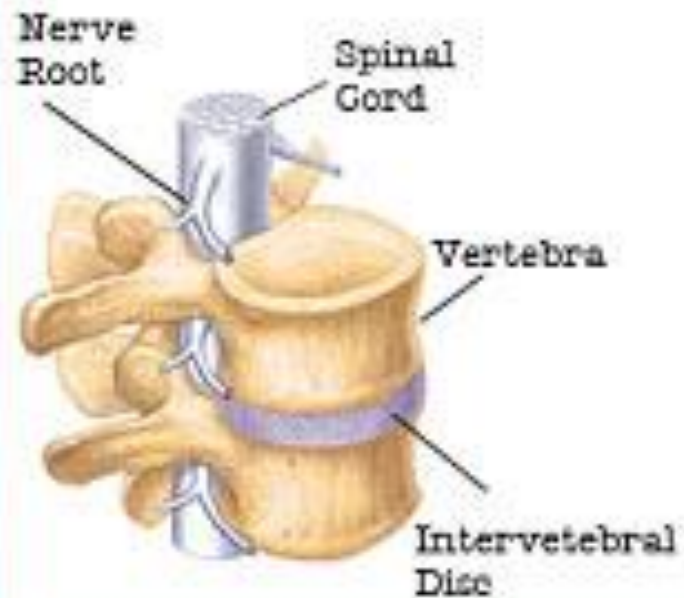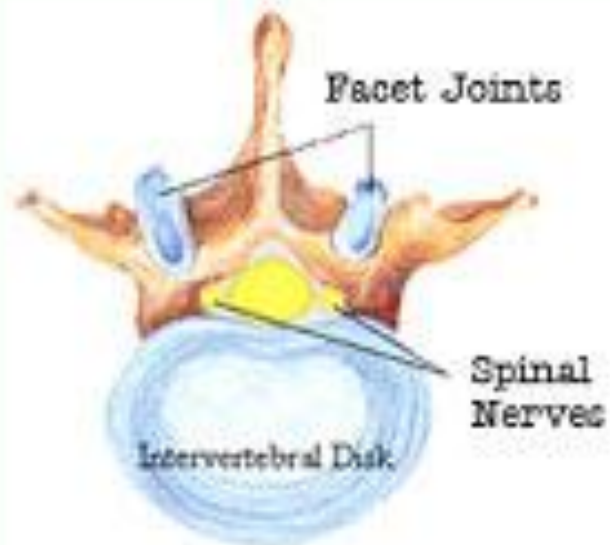Spiral Line

Superficial Back Line

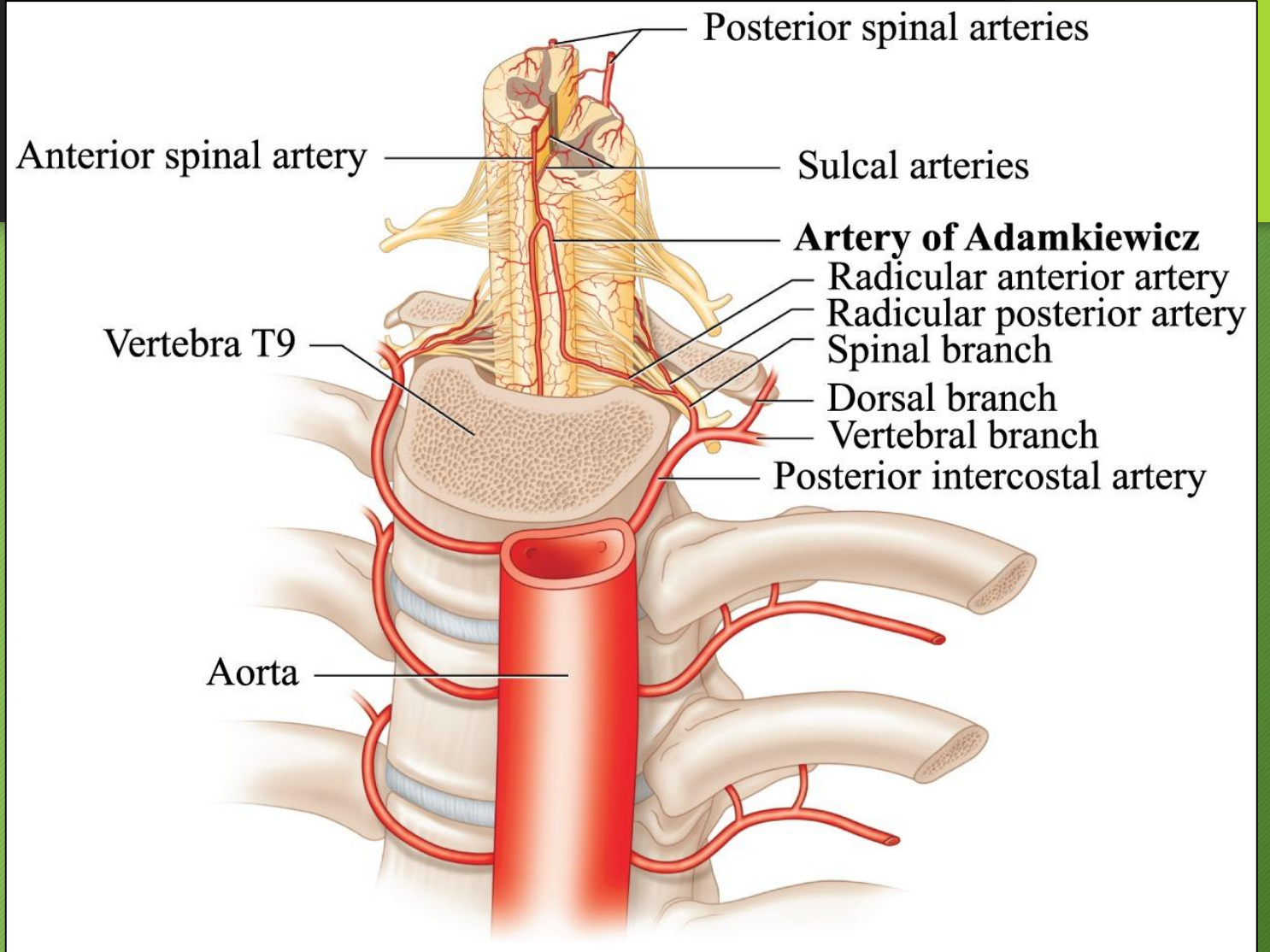
Superficial Front Line



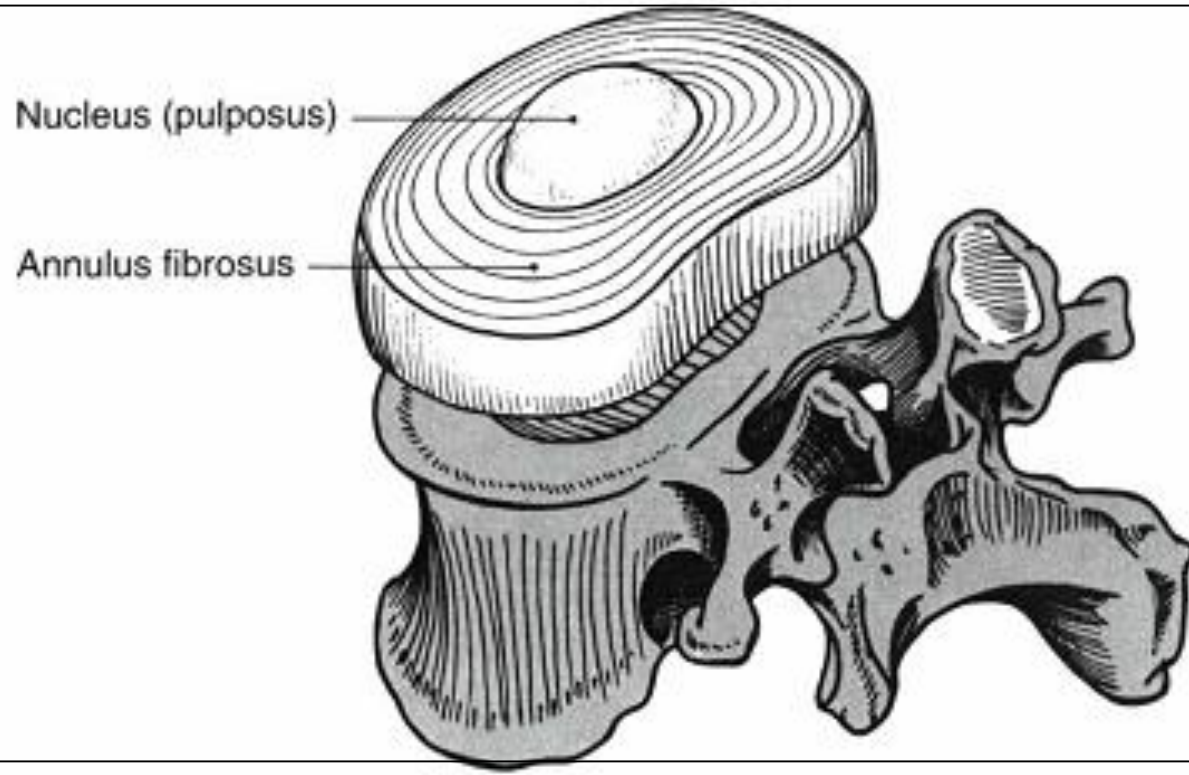
From the top



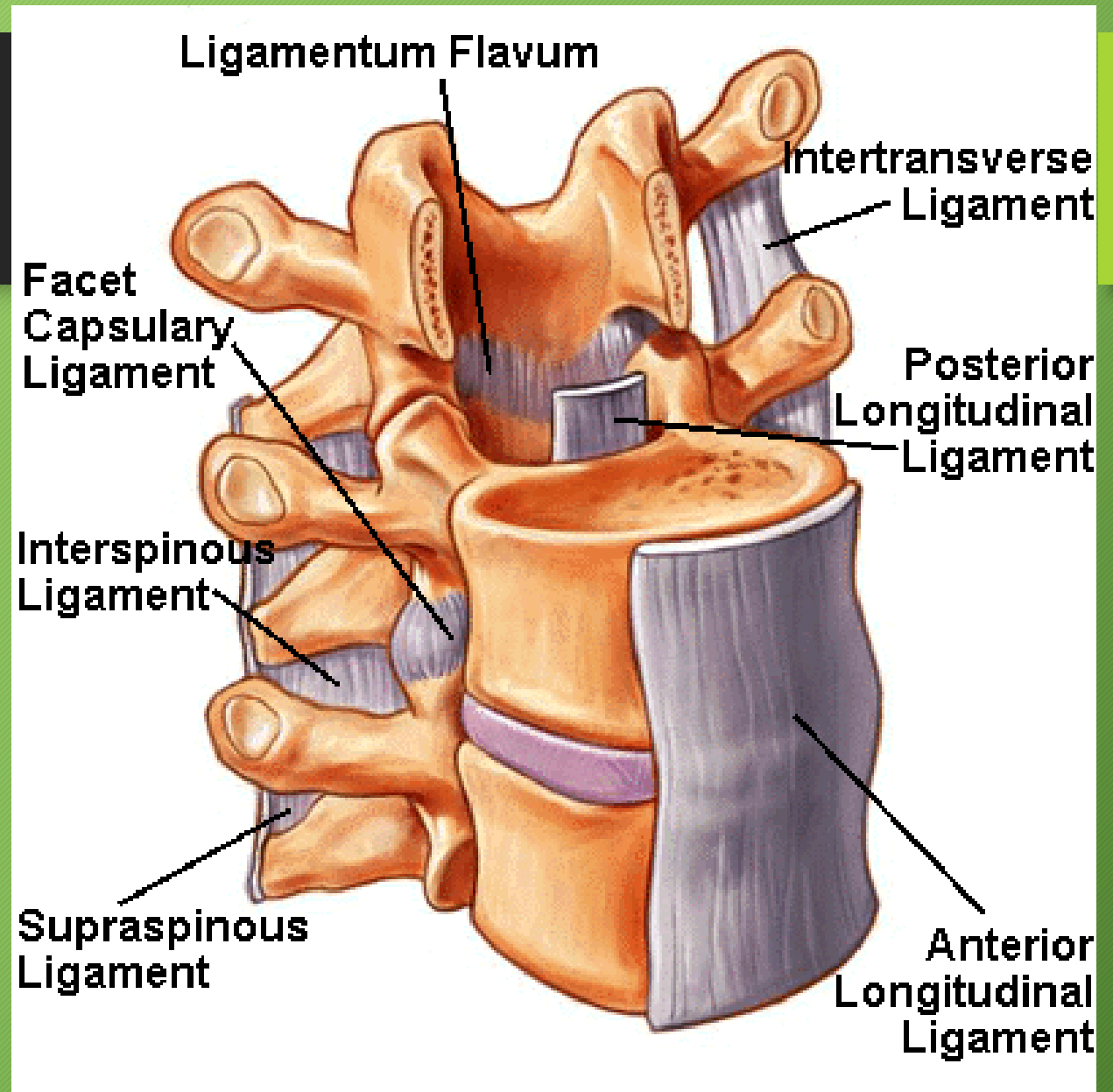
SPINAL ARTERIES



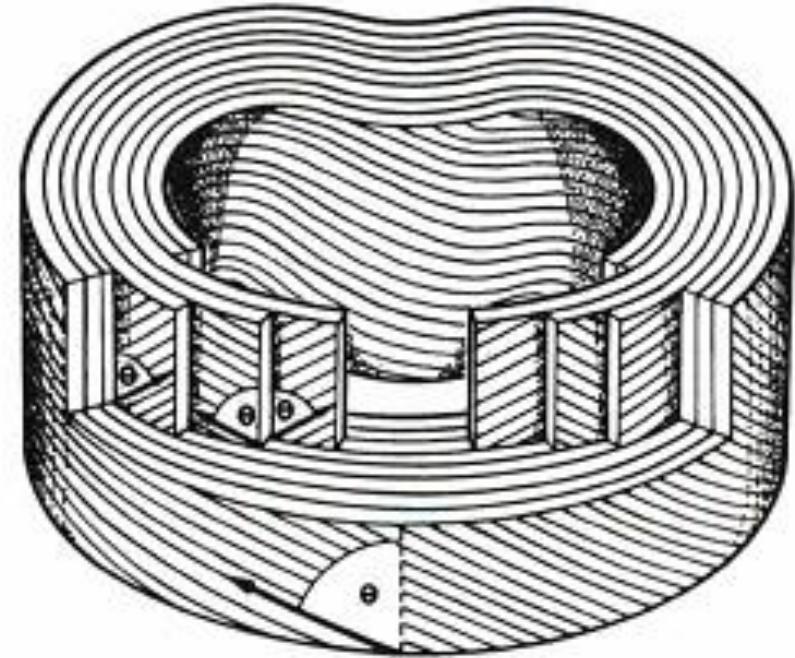
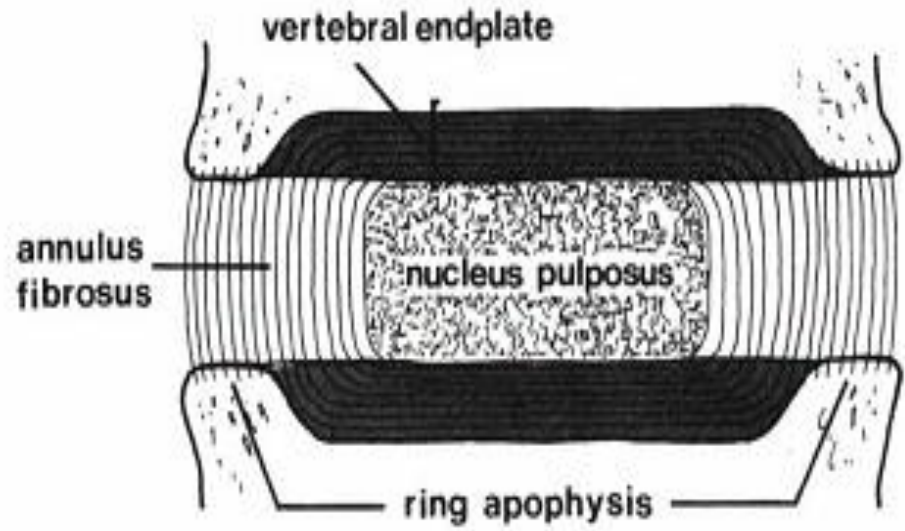
مهره و دیسک بین مهره

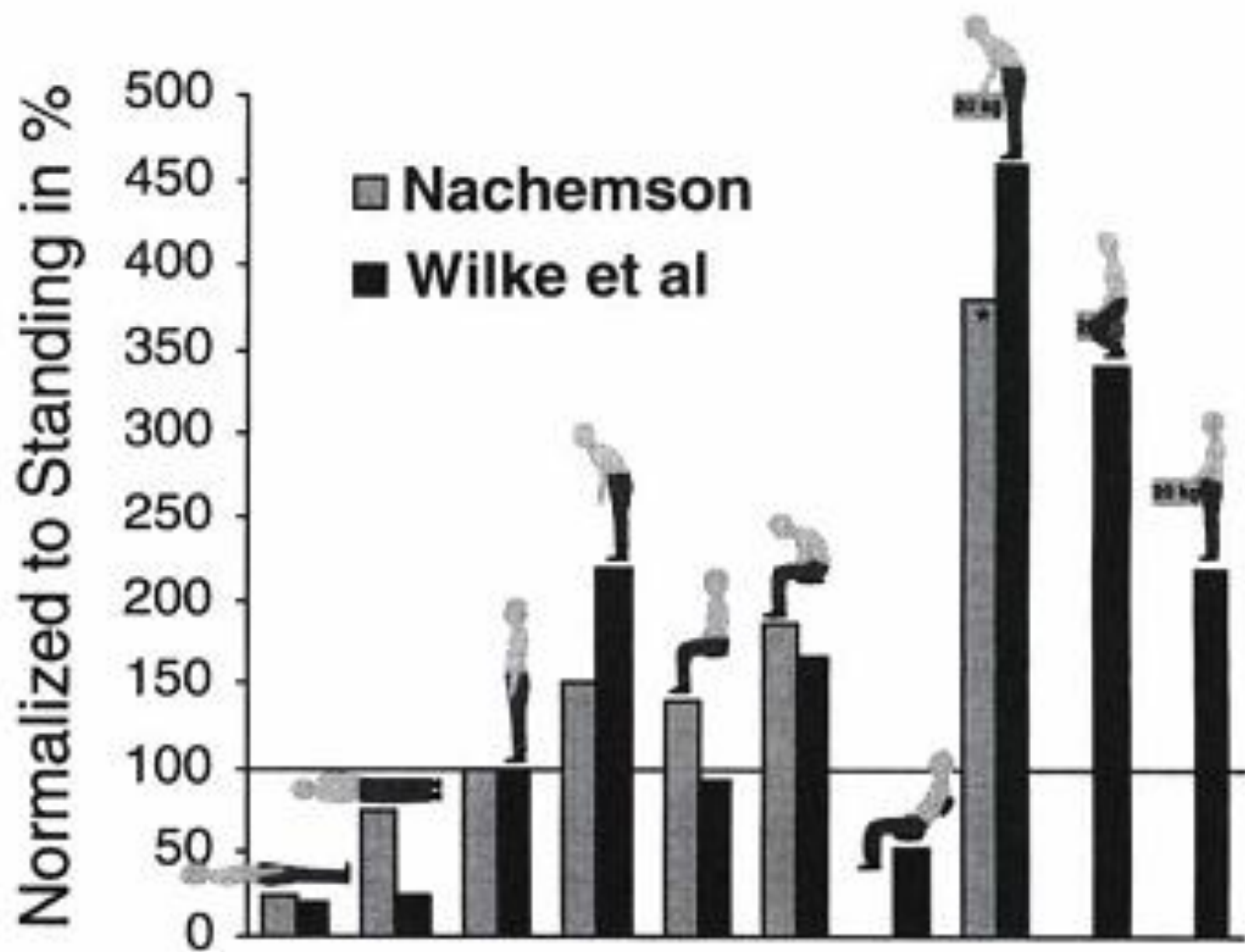


VERTEBRAL LIGAMENT



دیسک بین مهرہ ایی





RENG OF MOTION

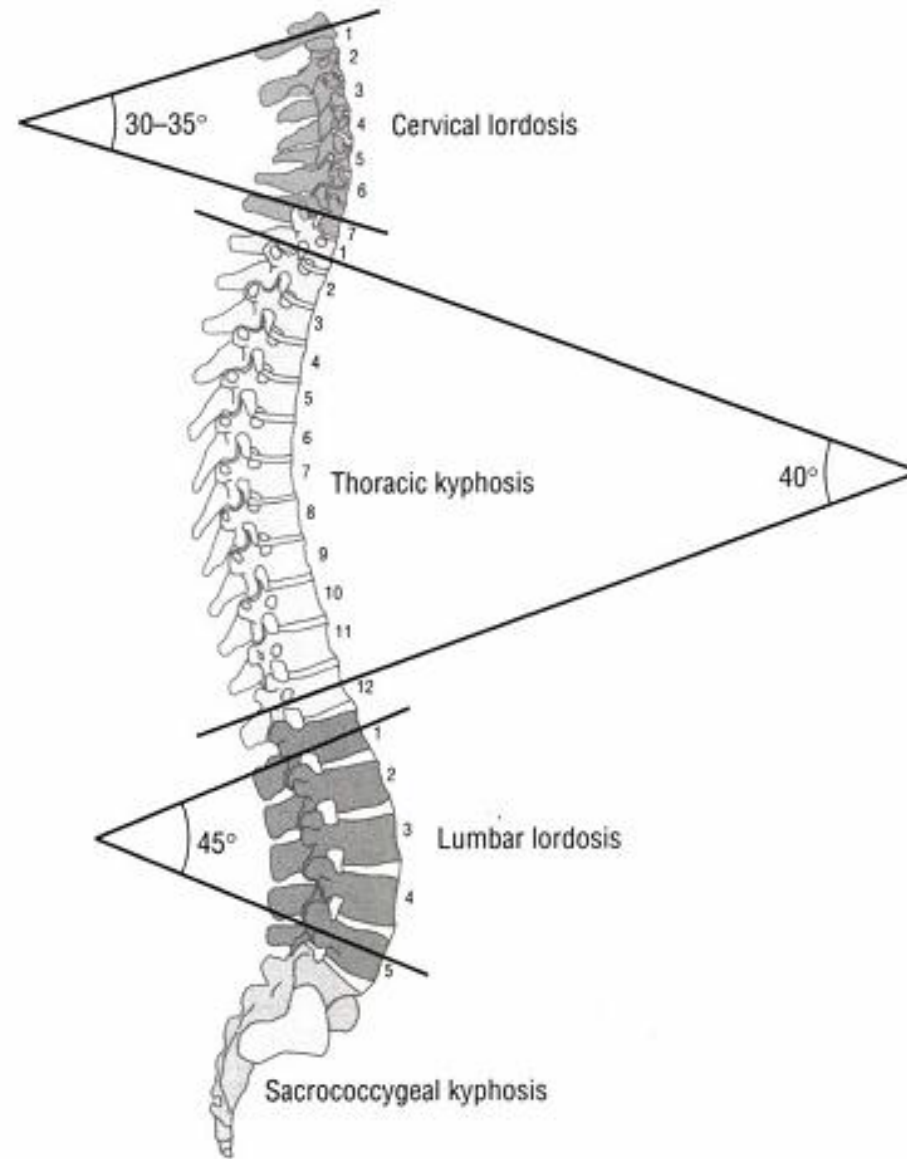


FIGURE 9–40. The normal sagittal plane curvatures across the regions of the vertebral column. The curvatures represent the normal resting postures of the region.

EXTENTION

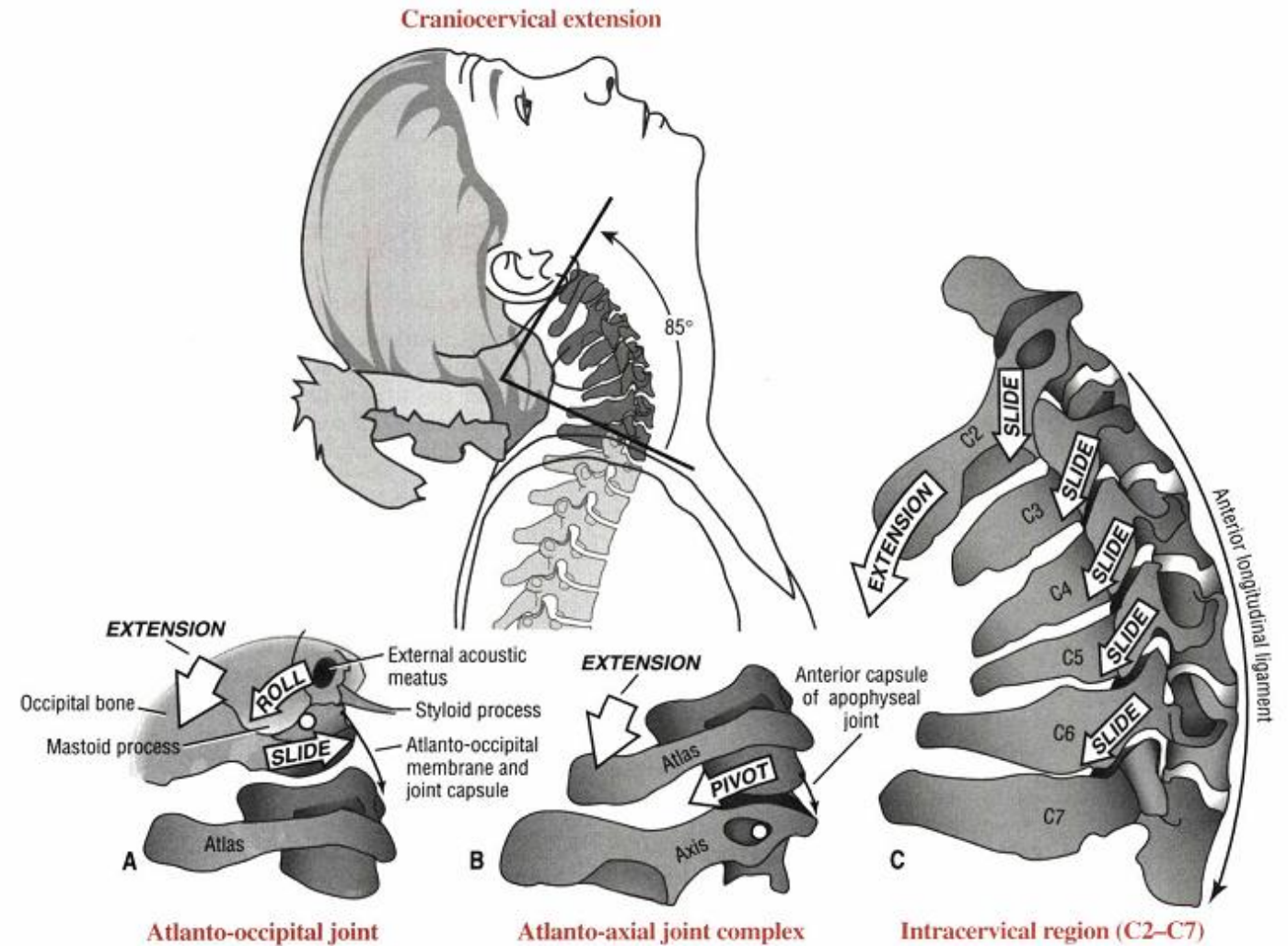


FIGURE 9-46. Kinematics of craniocervical extension. A, Atlanto-occipital joint. B, Atlanto-axial joint complex. C, Intracervical region (C2-7). Elongated and taut tissues are indicated by thin black arrows.

FLEXION

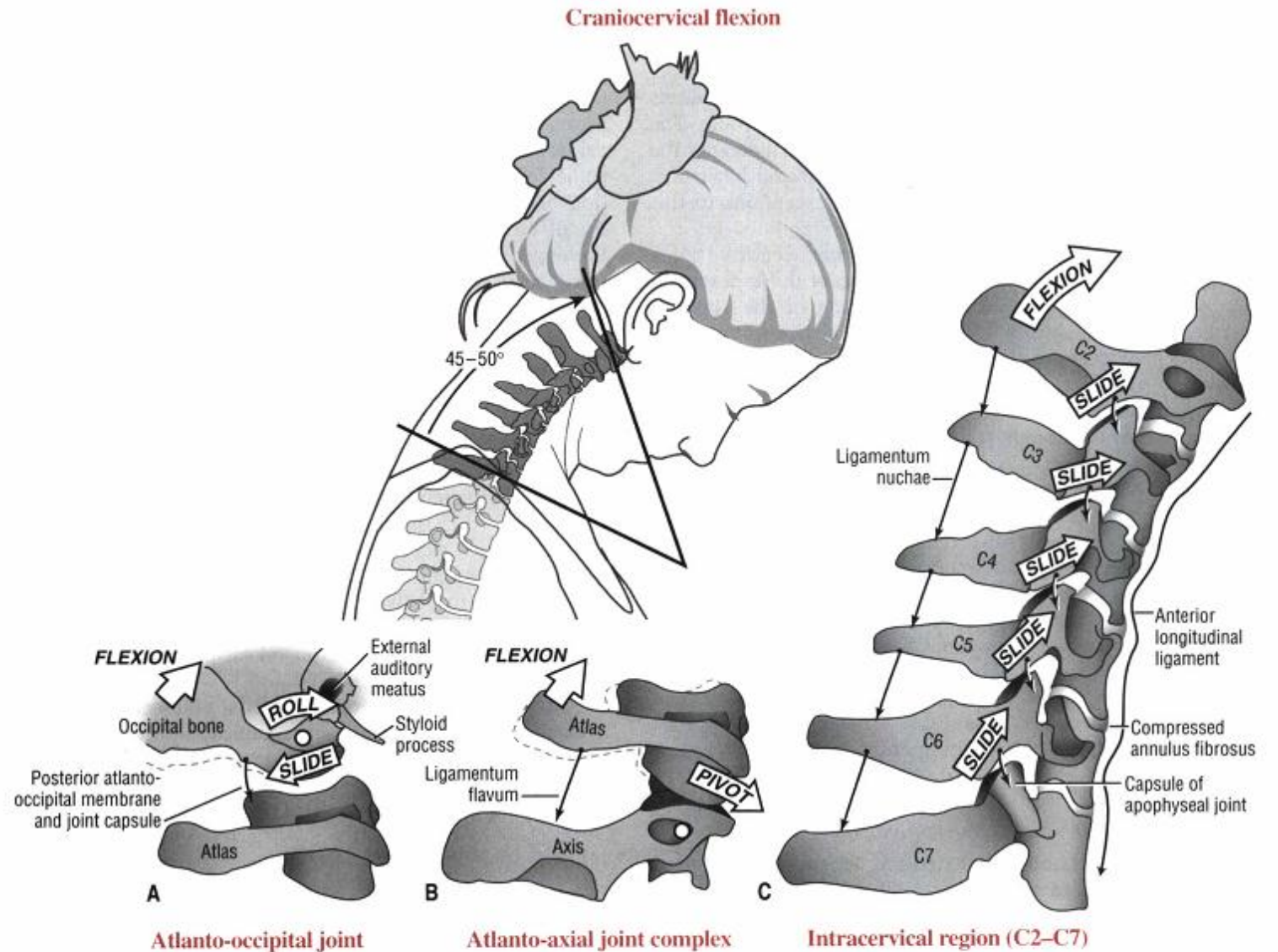


FIGURE 9-47. Kinematics of craniocervical flexion. A, Atlanto-occipital joint. B, Atlanto-axial joint complex. C, Intracervical region (C2-7). Note in C that flexion slackens the anterior longitudinal ligament and increases the space between the adjacent laminae and spinous processes. Elongated and taut tissues are indicated by thin black arrows; slackened tissue is indicated by a wavy black arrow.

LATERAL FLEXION

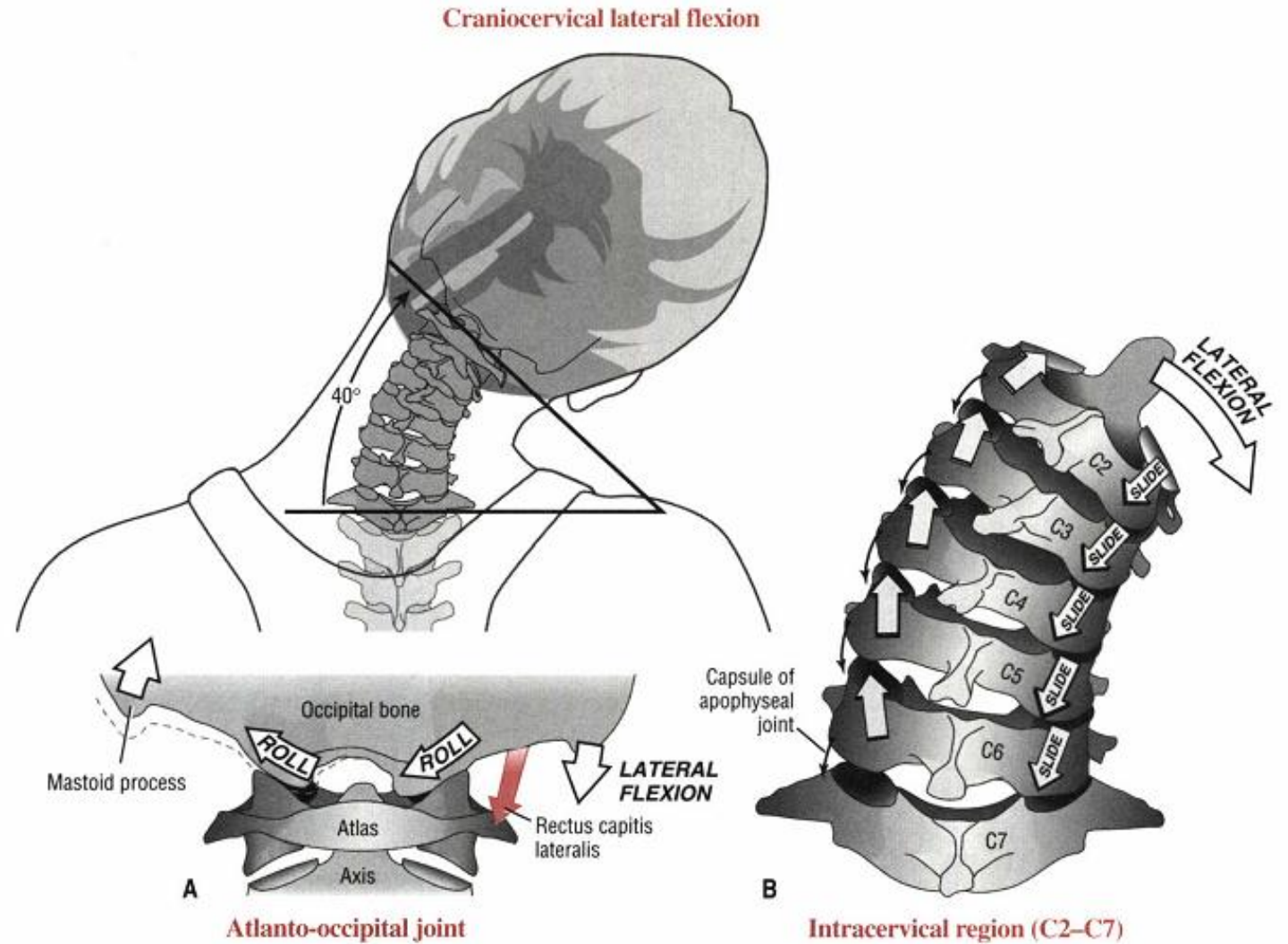


FIGURE 9-52. Kinematics of craniocervical lateral flexion. *A*, Atlanto-occipital joint. The primary function of the rectus capitis lateralis is to laterally flex this joint. Note the slight compression and distraction of the joint surfaces. *B*, Intracervical region (C2-7). Note the ipsilateral coupling pattern between axial rotation and lateral flexion (see text for further details). Elongated and taut tissue is indicated by thin black arrows.

ROTATION

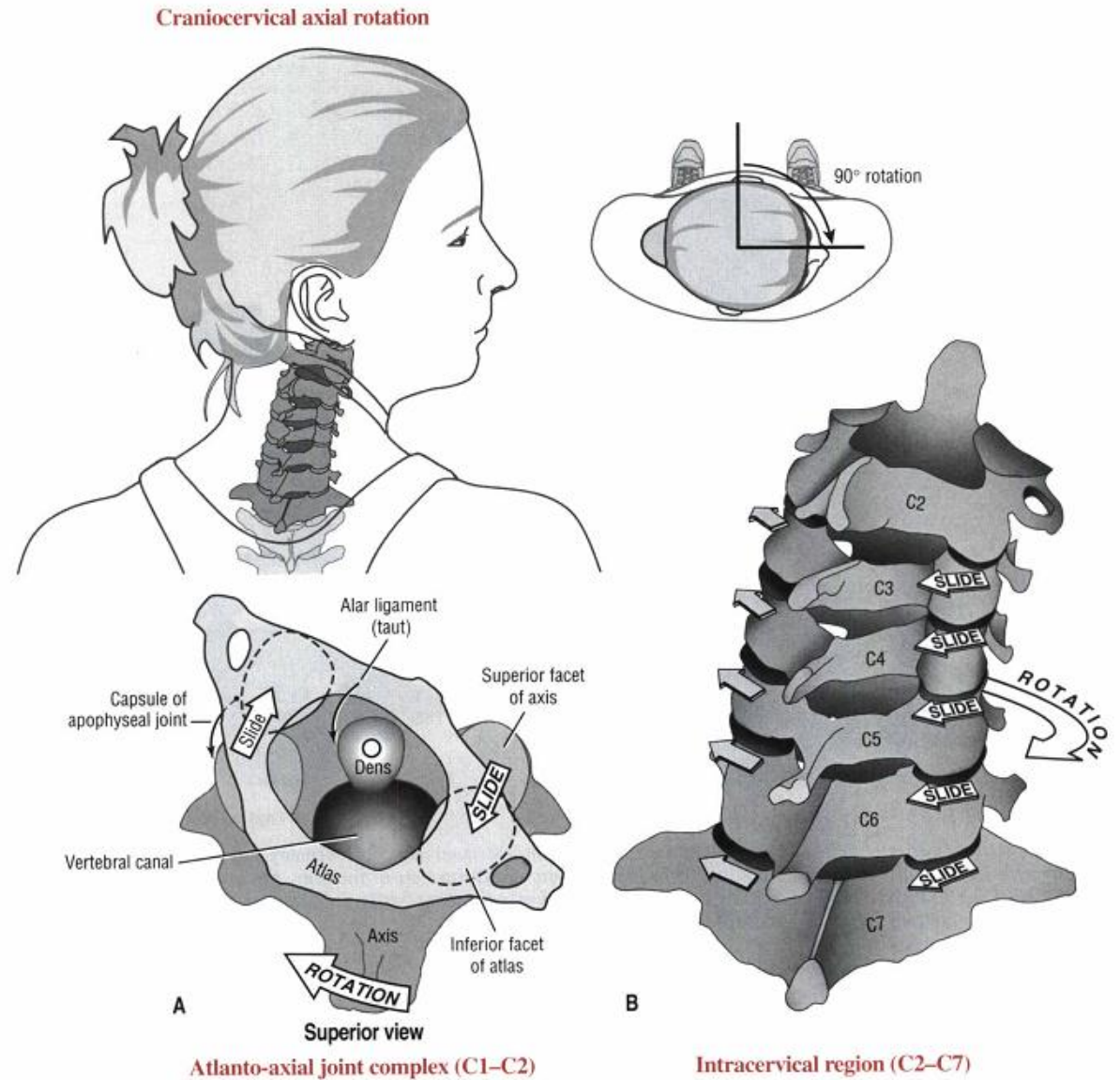


FIGURE 9-51. Kinematics of craniocervical axial rotation. A, Atlanto-axial joint complex. B, Intracervical region (C2-7).

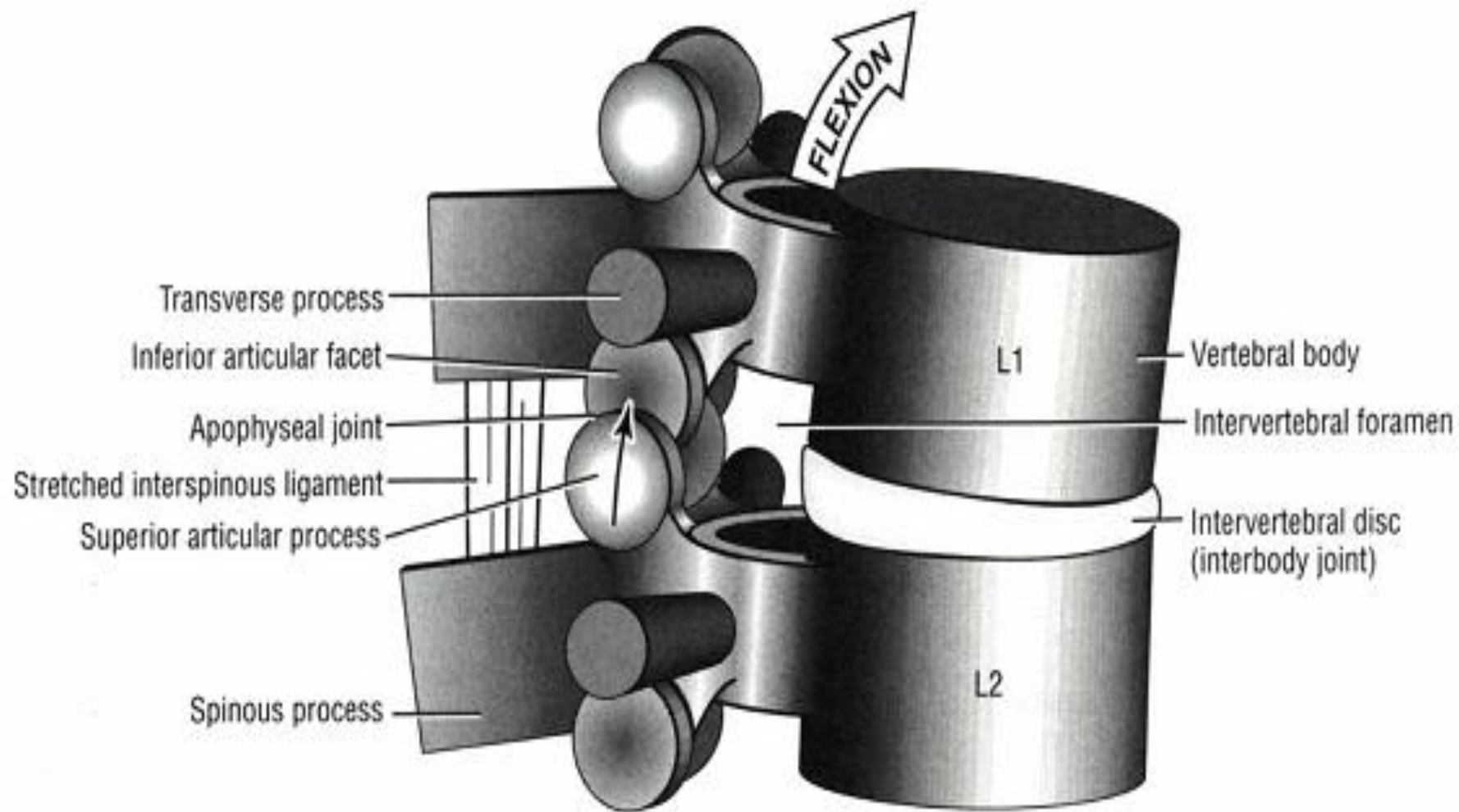
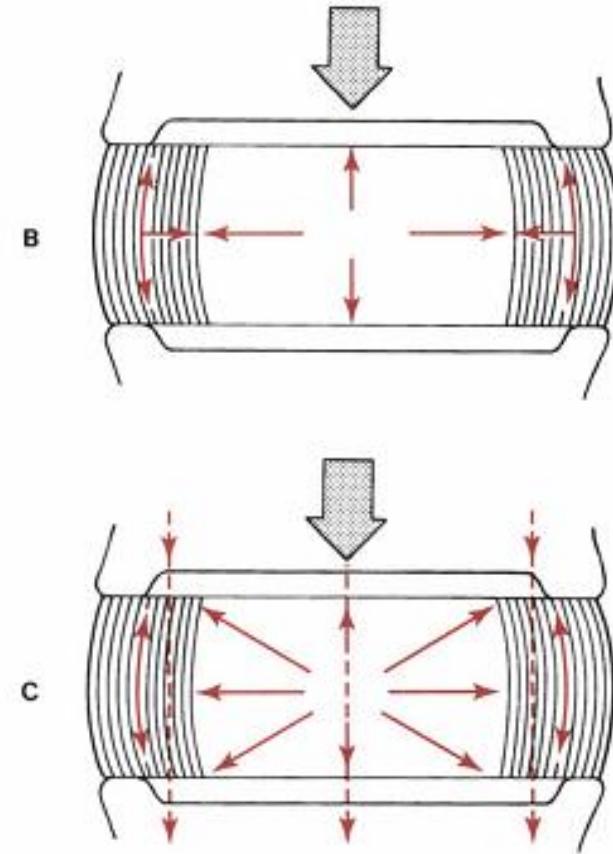
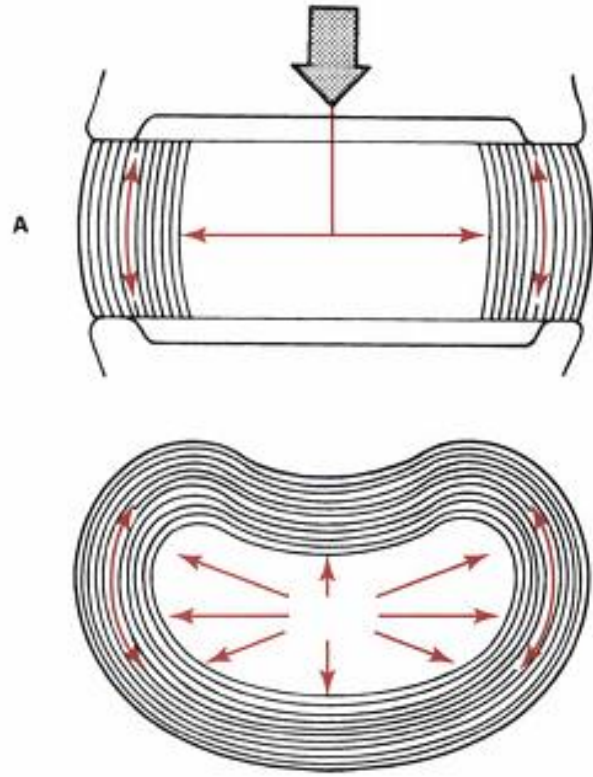
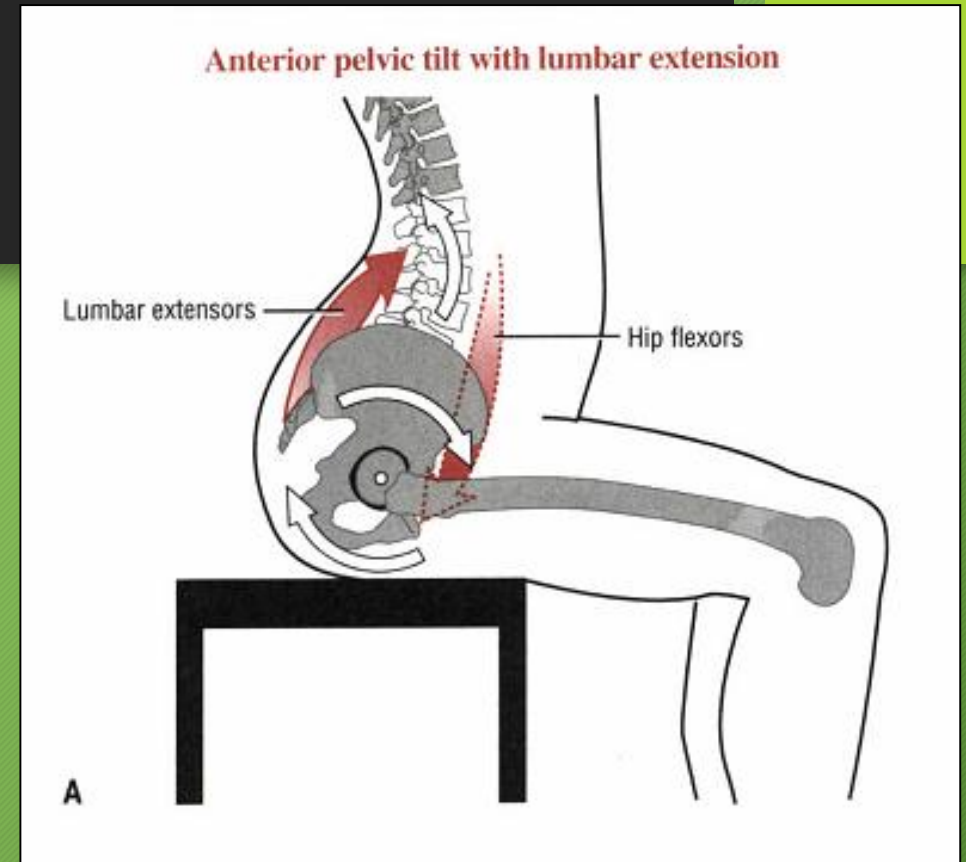
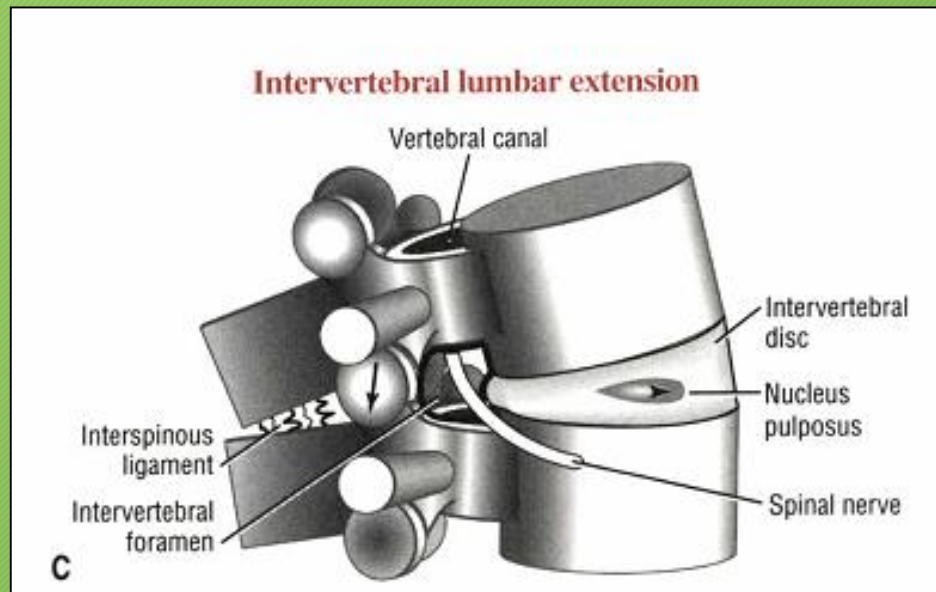


FIGURE 9-33. A model shows the three functional parts of a typical intervertebral junction: transverse and spinous processes, apophyseal joints, and interbody joint, including the intervertebral disc. The L1-2 junction is shown flexing and sliding between the articular facet surfaces of the apophyseal joints. The interspinous ligament is shown stretched. Note the compression of the front of the intervertebral disc.

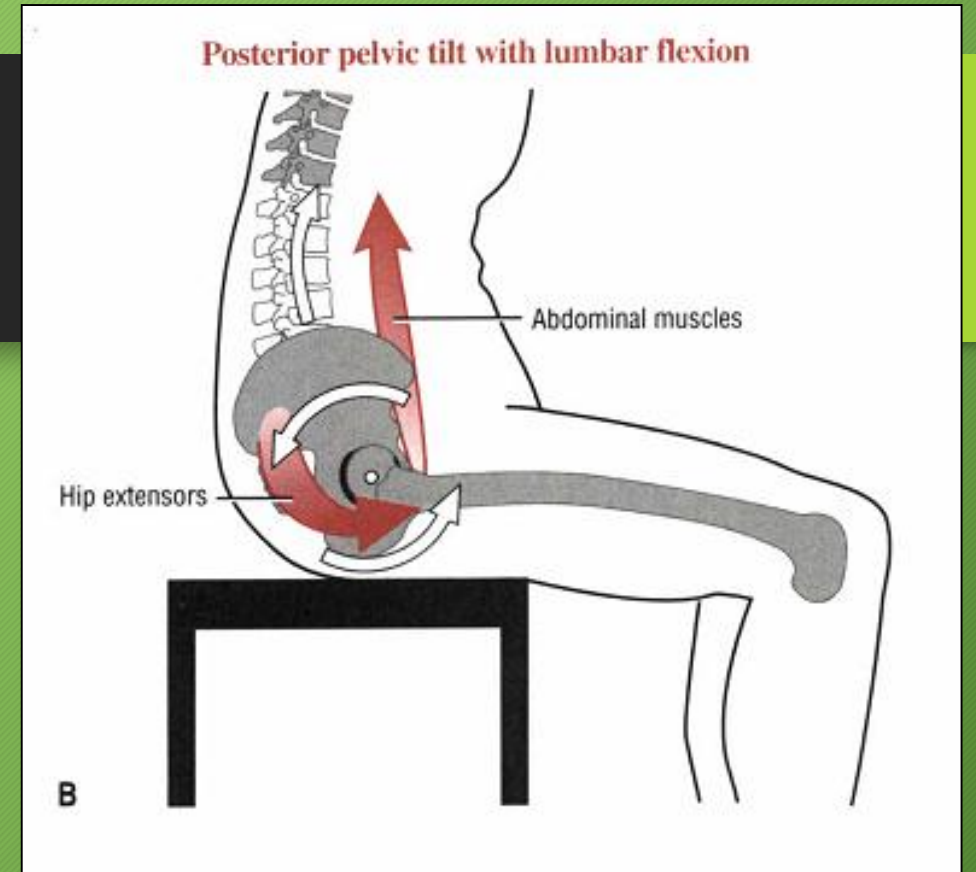
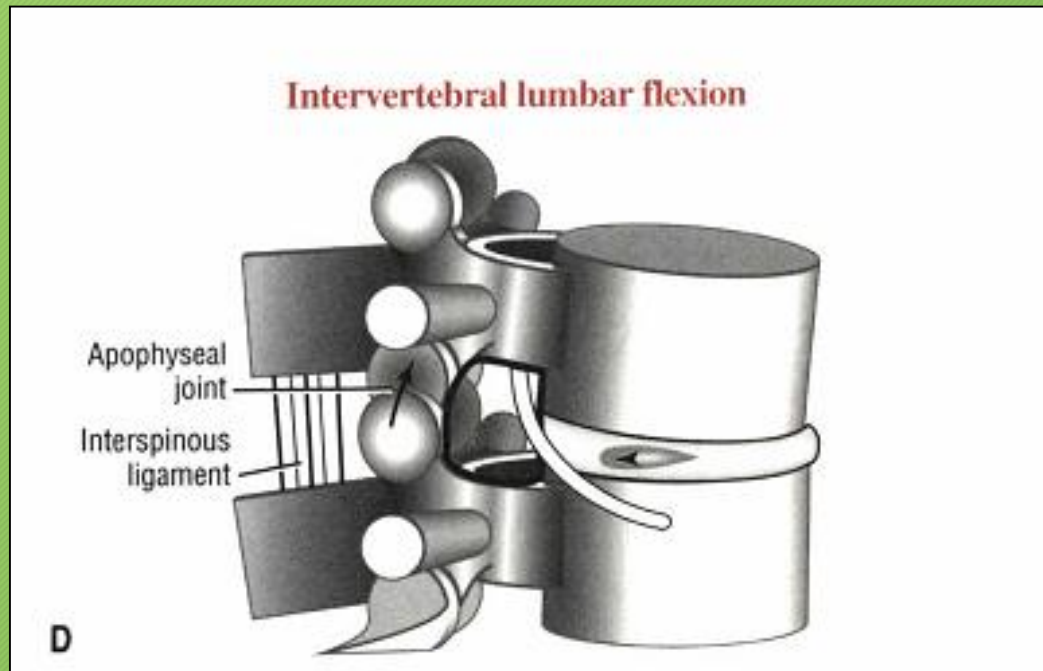
انتقال نیرو

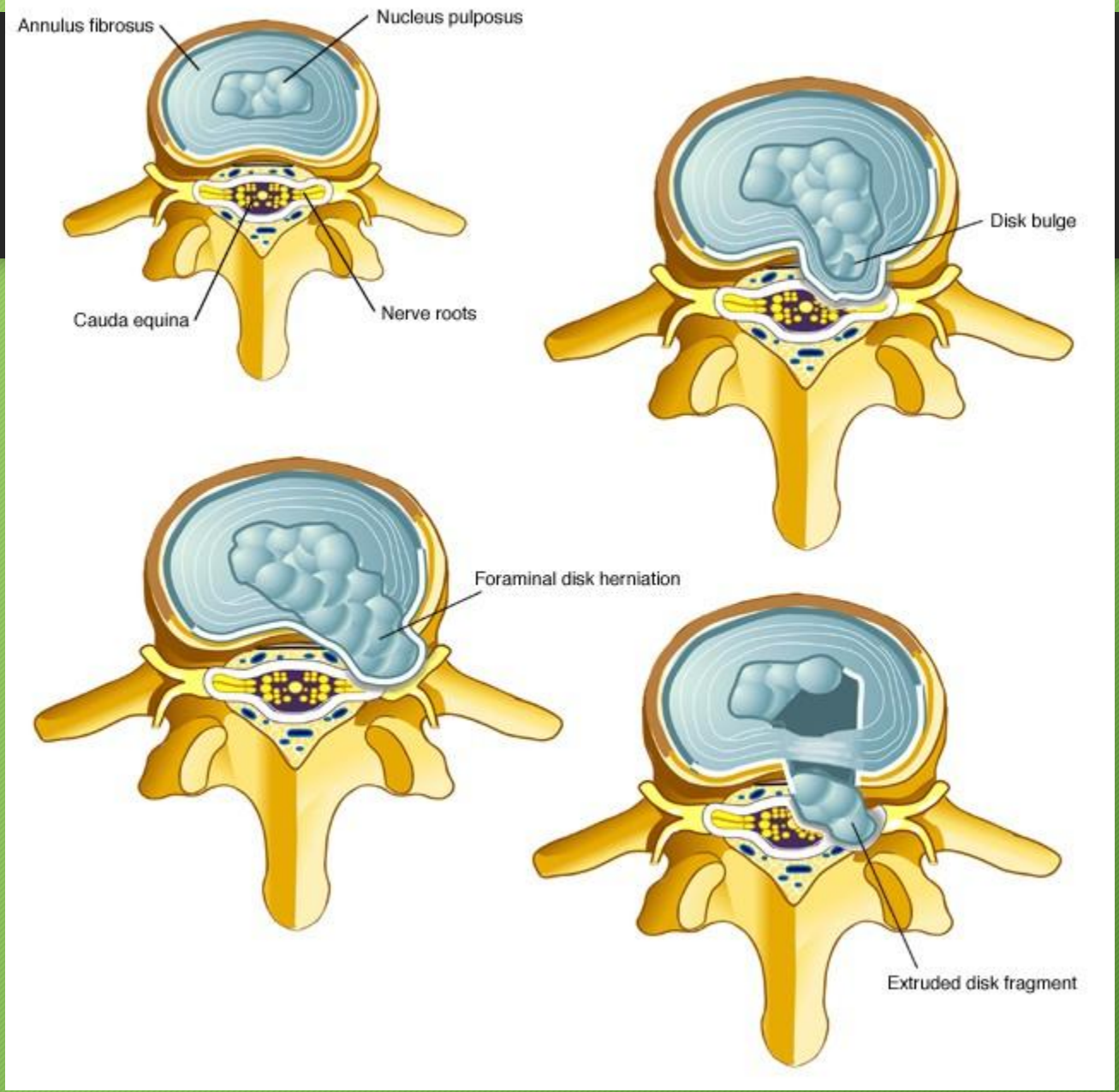


ANTERIOR PELVIC TILT



POSTERIOR PELVIC TILT







ANNE GEDDES®
www.annegeddes.com

© 1998 Anne Geddes